

Integrating Scar Tissue into the Fascial Web

Sharon Wheeler
Kristi Blessitt
Richard Ennis



Working with Scar Tissue

- ◆ Developed Scar Tissue Manipulation Called “ScarWork”
- ◆ ScarWork Results in a Tactile Change from Irregular Dense to Smooth
- ◆ Used Ultrasonography to See if ScarWork Indeed Changes the Scar Structure

ScarWork

Methodology

- ◆ Mindray DC-6 Doppler Ultrasound (2.5-6.0 MHz) used for all Imaging
- ◆ Three Subjects: Age 53 to 66 Years
- ◆ Abdominal Incision Scars: 12 to 43 years old
- ◆ Images: ~Two Weeks Before and up to ~Five Weeks After **One Hour** of **ScarWork**

ScarWork

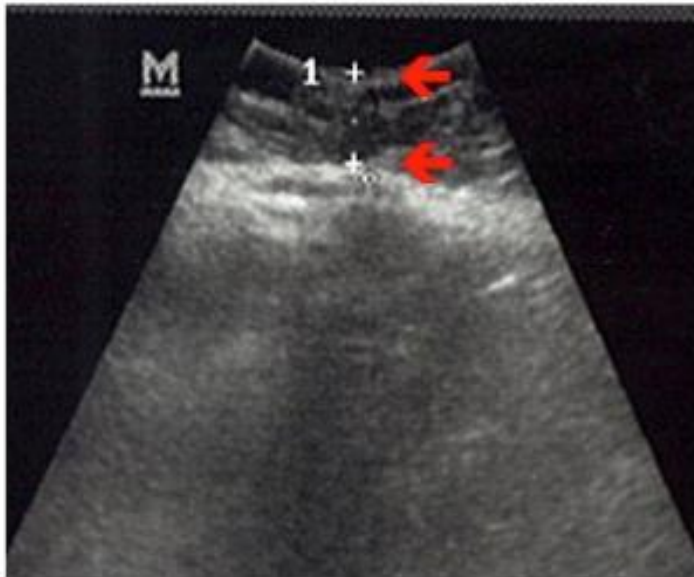
Subject #1

- ◆ Age 66 with 43-Year Old Scar
- ◆ Emergency Midline Abdominal Incision
- ◆ Dates
 - ◆ Before Image: January 6, 2012
 - ◆ Treatment: January 21, 2012
 - ◆ After Image: February 26, 2012

Subject #1

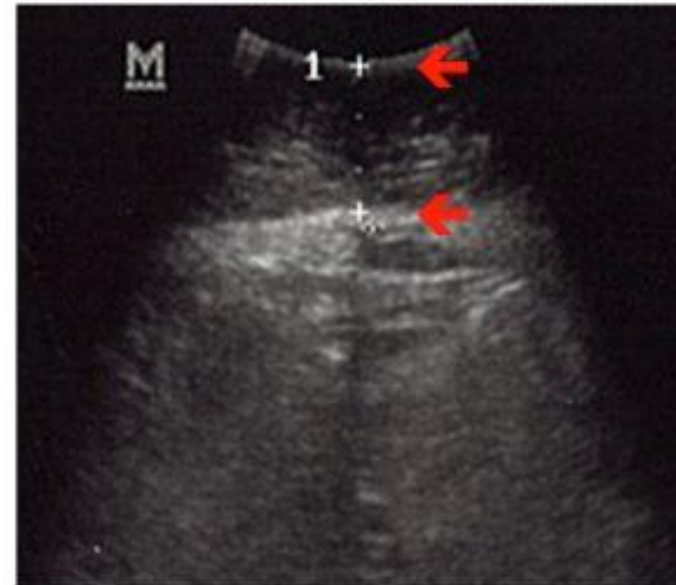Before

Skin to Scar: 1.79 cm



After

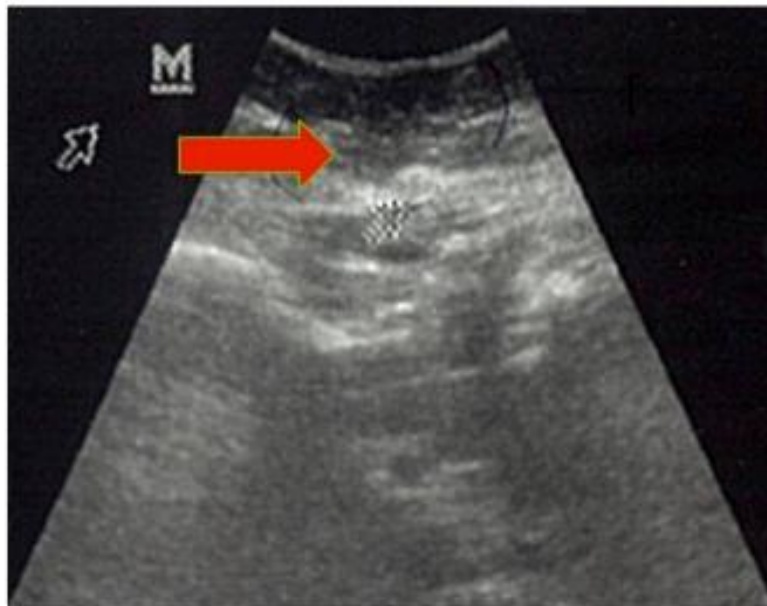
Skin to Scar: 2.74



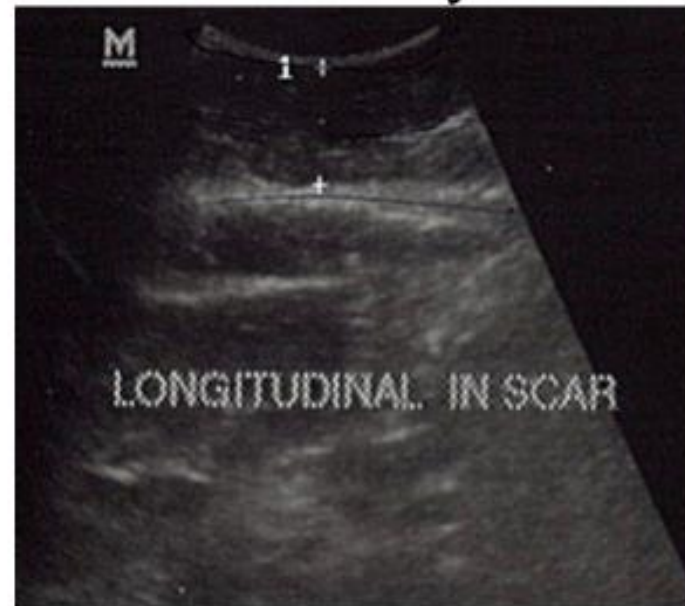
ScarWork

Subject #1

**Before:
Fascial “Bleb at Closure**



**After: Restoration of
Normal layers**



ScarWork

Subject #1 Observations

Observations

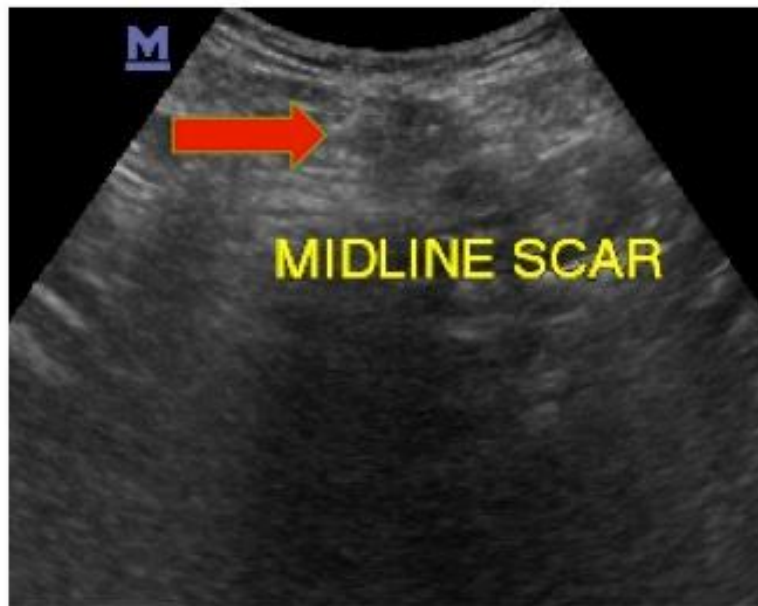- ◆ Skin-to-Scar Distance changed from 1.79 cm to 2.74 cm After ScarWork
- ◆ Fascial Bleb at area of Closure Changed in Appearance to “Normal Layers of Tension”

Subject #2

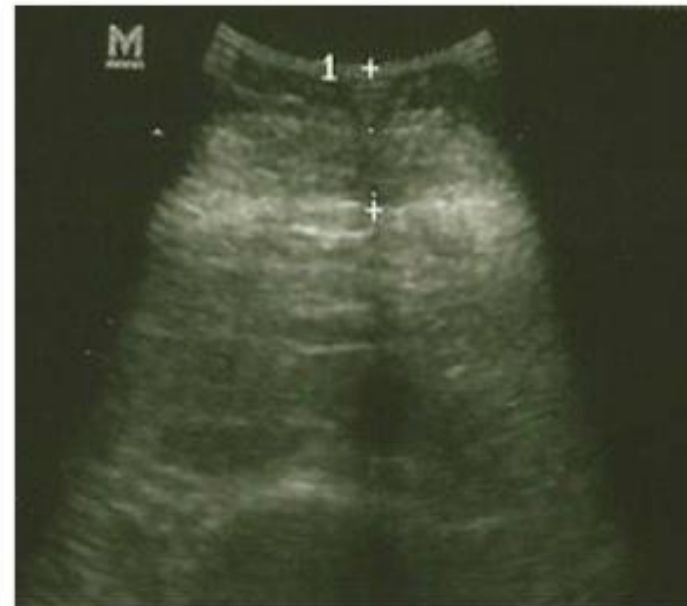- ◆ Age 58 with Three Abdominal Scars
- ◆ Illeoanal Anastamoses (2) – 20 & 22 Years Old
- ◆ C-Section - 15 Years Old
- ◆ Dates
 - ◆ Before Image: July 1, 2012
 - ◆ Treatment: July 16, 2012
 - ◆ After Image: August 3, 2012

Subject #2 Left Lateral

**Before:
Incision Scar**



**After: 2.25 cm Depth,
Reduced Scar Size**



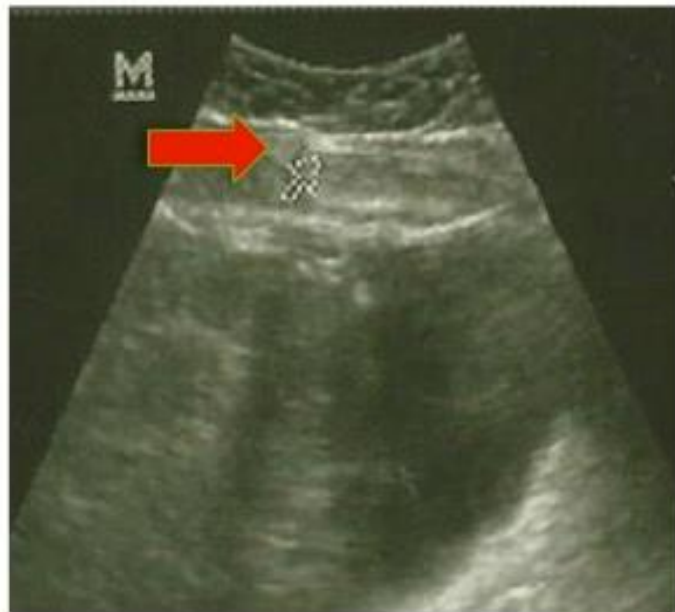ScarWork

Subject #3

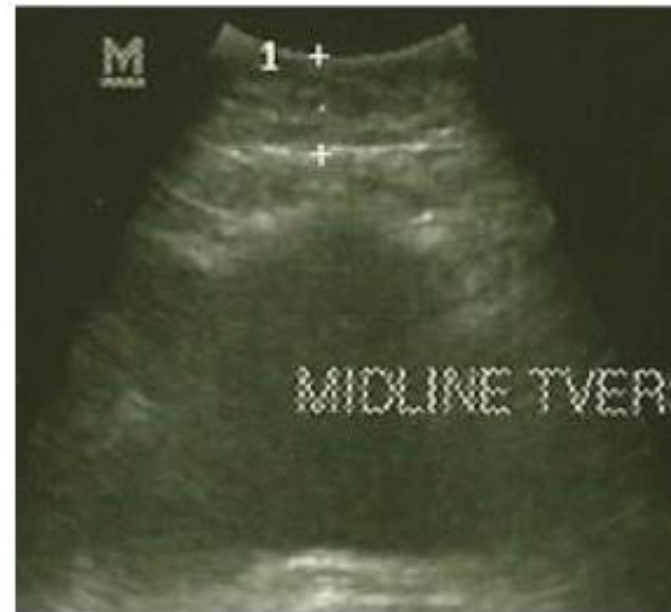- ◆ Age 63 with Three Scars
- ◆ 30-Year Old Tubal Pregnancy Scar
- ◆ 27-year Old Cesarean Section
- ◆ 12 Year Old Hysterectomy
- ◆ Dates:
 - ◆ Before Image: July 16, 2012
 - ◆ Treatment July 16, 2012
 - ◆ After Image: July 22, 2012

Subject #3

**Before: Tethering
Effect at Arrow**



**After: Showing
“Release” of Tether**

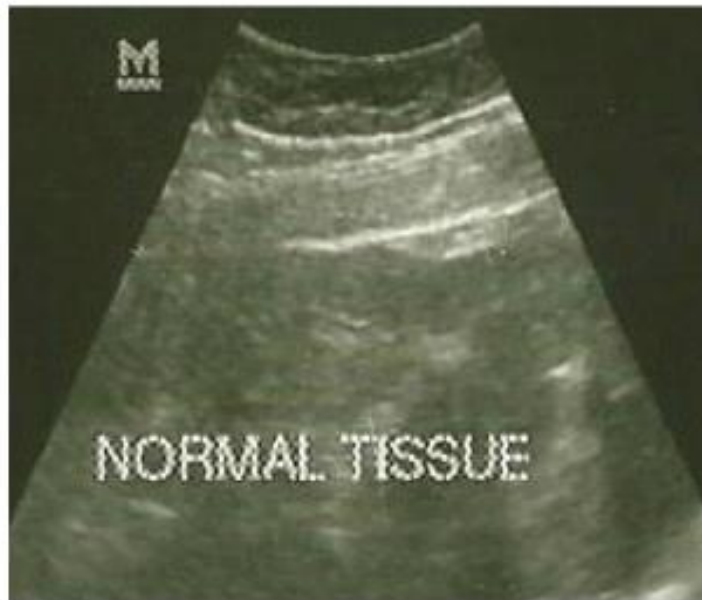

ScarWork

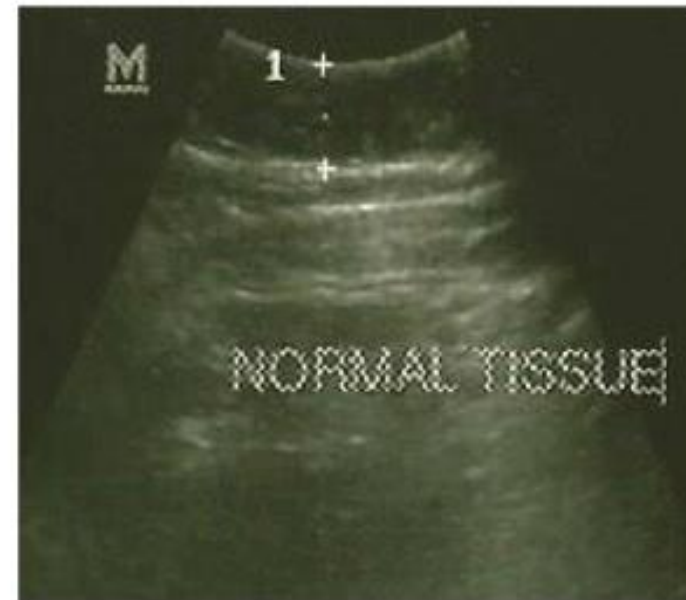
Subject #3

Normal Tissue - Control Images

Before



After



ScarWork

Subject #3 Observations

Observations

- ◆ Tethering Effect was reduced in all views after ScarWork
- ◆ Normal Tissue (Control) was not affected by ScarWork

Conclusion

- ◆ **ScarWork** does not Affect Normal Tissue
- ◆ **ScarWork** does affect Scar Tissue
- ◆ **ScarWork** may be Useful for the Remediation of Mature Scars.

ScarWork

Co-Authors

- ◆ Dr Kristi Blessitt, MD

- ◆ Sonography
- ◆ Image Interpretation



- ◆ Richard Ennis, MS, Rolfer™

- ◆ Technical Input and Writing



ScarWork